

The Posterior Palatal Seal: A Review

Susheen Gajare¹, Ajit Jankar², Suresh Kamble³, Bhushan Bangar⁴, Sandeep Fere⁵, Yogita Mundada⁶

^{1,5}Reader, ²Professor & HOD, ³Principal & Professor, ⁴Professor, ⁶Post Graduate Student.

Department of Prosthodontics, MIDSR Dental College, Latur, Maharashtra

Abstract:

Complete dentures may suffer from a lack of proper border extensions, but in the complete maxillary dentures, the posterior palatal seal is more important. The posterior-most border ends on the surface, which is movable to some degrees and not at the point of tissues like the other borders. A complete denture with significant retention will aid in the patient's comfort, psychological, and functional factors. Maxillary dentures retention depends on considerations of both dentures and patients. In complete maxillary dentures, border seal in the posterior region is taken care of by the proper recording of the Posterior Palatal Seal (PPS) area. Absence of a posterior palatal seal and improper formation of distal palatal length are the reasons for the lack of success of many maxillary complete dentures. This article aims to offer adequate information on methods and importance of recording posterior palatal seal of complete denture.

Keywords: Post palatal seal, complete denture retention.

Corresponding Author: Yogita Mundada, PG Student, Prosthodontics, MIDSR Dental College, Latur. Email id.: yogamundada123@gmail.com

INTRODUCTION:

The tissue supported complete denture is the most preferred treatment of choice for edentulous patients, and their success depends on the relationship between anatomic structures and dentures that support them.¹ Numerous factors contribute to the success of complete denture, one of them being a precise recording of the border seal. Under extension or overextension of the border, a seal will lead to loss of retention, support, and stability. Skinner stated that "The most useful addition to increasing retention is post dam."² Only adequate border seal resists horizontal forces and lateral torquing of the maxillary denture.

Therefore, the proper placement of the Posterior palatal seal commands a specific protocol of clinical procedure, which creates an optimally retentive complete maxillary prosthesis.³

DEFINITION

According to Glossary of Prosthodontics Terms-9, "Posterior palatal seal is defined as a portion of the intaglio surface of a maxillary removable complete denture, located at its posterior border, which places pressure, within physiologic limits on the posterior palatal seal area. This seal ensures intimate contact of the denture base to the soft palate and improves retention of the denture."⁴

The rationale of Posterior Palatal Seal

- Posterior palatal seal aids in the retention of complete denture.⁵
- It serves as a barrier and prevents ingress of fluid, food, the air between denture, and tissue Surface.⁵
- It helps in decreasing gag reflex by maintaining positive contact with moving soft palate.⁶
- It guides the positioning of the custom tray during the final impression.⁵
- By providing a thick border, it compensates the war page that occurs during polymerization.⁵
- It provides comfort and confidence to the patient by increasing the retention of denture.⁷

Techniques of Recording Posterior Palatal Seal

According to Hardy and Kapur, there are three techniques of recording the posterior palatal seal:

1) Functional or Physiologic Technique: It is a technique in which the tissues, displacing within its physiologic limits. A low melting wax/soft stick modelling wax is border melded in the posterior palatal seal area of the final impression by functional movements made by the patient.

i) Fluid Wax Technique: This technique is also known as the physiological impression technique. It is done immediately after the final impression and before pouring the master cast. Zinc oxide eugenol or impression plaster preferred over to them. Types of wax utilizing for this technique are 1) Iowa wax, 2) Korecta wax, 3) H-L physiologic paste, and 4) Adaptol green. These waxes are mouth temperature impression waxes. They displace soft tissues within their physiological limits before the waxes themselves are displacing.⁸Slight excess amount of melted wax is painted onto the impression surface within the outline of the seal area by using a camel hairbrush. It is then allowed to cool to below mouth temperature,

thus increases its consistency. During the insertion of impression, the position of the patient's head is maintaining at the location such that Frankfort's horizontal plane makes a 30° below the horizontal plane. The patient's tongue is firmly positioning against the mandibular anterior or handle of the maxillary custom tray in case of entirely edentulous patients.⁹Now, the impression is inserted to the mouth for 3 min without pressure. Then pressure is applied for another 3 min. Ask the patient to periodically rotate the head for recording all functional positions of the soft palate. Upon removal of the impression, check for the glossiness of the surface. If not, add more wax, and repeat the procedure. Later, use a sharp blade to trim off excess wax till the feather edge margins obtain. The wax is allowed to air cool, and then, the impression is boxed and poured with dental stone.¹⁰

ii) Semi Functional Technique: The dentist does border molding. Border molding is "determining the extension of a prosthesis by using tissue function or manual manipulation of the tissues to shape the border areas of an impression material" - GPT 9

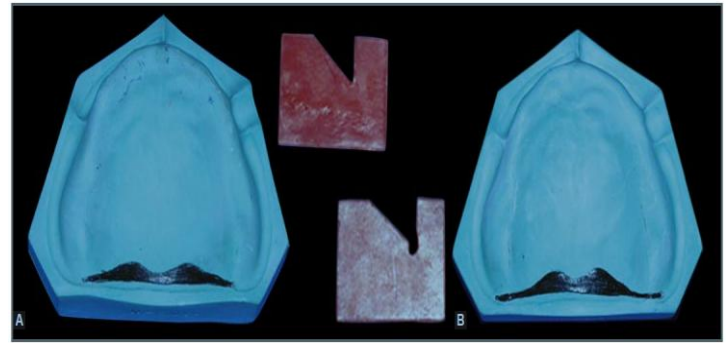
2) Empirical Technique: Developed on the cast by grooving it to the desired depth.

i) Conventional Technique: Pour the cast after making a final impression. Construct a trial base by using a shellac base plate or well-adapted self-cured resin. Ask the patient to rinse with mouthwash to remove ropy saliva that might interfere with the transfer of marking.^{11,12}Then, gauze is used to dry the posterior palatal area and palpate the hamular process with a T burnisher or mouth mirror. Mark the extent of the hamular notch with an indelible pencil. Mark the posterior vibrating line by asking the patient to say "ah" in a non-vigorous manner. The marked line connecting the hamular notch and a posterior vibrating marking will form the posterior border of the denture. The trial base is

inserted into the patient's mouth so that indelible markings are transferring to it. Then, the trial base is seated on the master cast to transfer the markings marked in the patient's mouth to the cast. Trim the trial base to the posterior border. Now, the anterior vibrating line is marked with the methods mentioned earlier and transferred to the master cast. Score the area between the anterior and posterior vibrating lines in the master cast to a depth of approximating 1-1.5 mm on either side of the median palatine raphe. Meanwhile, in the region of the median palatine raphe, it is scraped to the extent of approximating 0.5-1.0 mm because it has little submucosa and cannot withstand the same compressive force as the tissue lateral to it. The scraped areas should taper progressively shallower both anteriorly and posteriorly. Because of that, it blends with the palatal tissue. This entire border of the post dam resembles the shape of a Cupid's bow. The shellac trial base should be softened and readapted. If a resin trial base is using, then the cast is coated with cold mold seal, and add auto polymerizing resin to the scored areas. The modified trial base is now placed into the patient's mouth and checked for any separation of the record base and tissue.

ii) Boucher's Technique^{13, 14}: The width of the posterior palatal seal is limited to a bead on the denture that is 1.5 mm deep and 1.5 mm broad at its base with a sharp apex. Finally, it is a beaded posterior palatal seal.

iii) Bernard Levin's Technique^{15, 14}: It is for class III soft palate forms: He described a "double bead" technique for class III soft palate. In this technique, scrape a depth of about 1mm and a width of 1.5mm in the posterior vibrating line. A distance 3 - 4 mm from the posterior border, the anterior vibrating line region is beaded. It is known as a rescue bead.

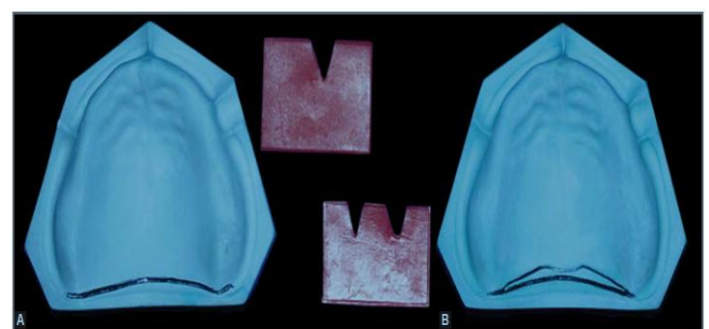


A) Single Bead
(Boucher's technique)

B) Double Bead
(Bernard Levin's
Technique)

iv) Swenson's Technique¹⁶: Cut a groove along a posterior line to a depth of 1 - 1.5 mm that will cause the posterior border to stand straight out from the hard palate, turning neither up nor down. Taper posterior line towards the anterior line by scraping the cast.

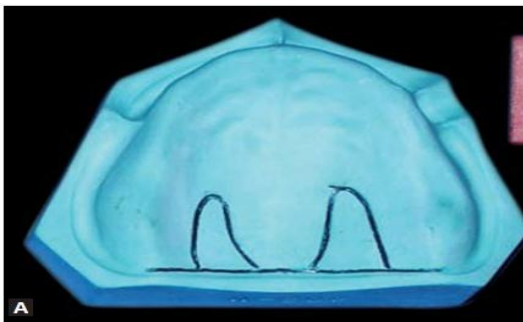
v) Calomeni, Feldman, and Kuebker's Technique^{12, 14}: In this technique, a depth of 1 - 1.5 mm scraped as a posterior-most bead in which extends through hamular notches and distance of 5 - 6 mm from the scraped posterior line, the anterior line is beaded. Using a Kingsley scraper No.1, scrape, depth 0 at the anterior line to the extent of 1 - 1.5 mm along the posterior border. A distance of 2 - 3 mm should be present in between the anterior and posterior lines from the midline.



A) Butterfly
(Swenson's technique)

B) Butterfly with bead
(Calomeni's technique)

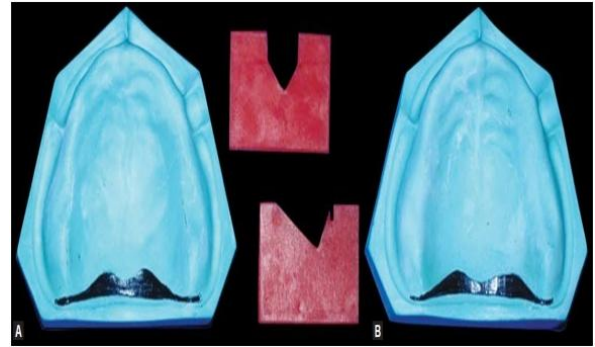
vi) Pound's Technique^{17, 14}: Pound recommends a single bead posterior palatal seal with anterior extensions for additional air seal. In the palate from the hamular notch to hamular notch, a 'V' shaped groove is carved, measuring a width of 1 to 1.5 mm and place depth of 1 to 1.5 mm and 2 mm anterior to vibrating line. Carve a loop on either side of the midline to provide an adequate air seal. Palpate the area with a blunt of the instrument to determine the width of the anterior loop.



A) Pound's technique

vii) Silverman's Technique¹⁸: Pencil is used to draw a line from hamulus to hamulus midway between the anterior and posterior flexion lines. Score the posterior-most flexion line to one-half deep of that of the mid scoreline. Mark the anterior flexion line with a shallow scratch and taper the deepness of the cast from the midline to the anterior and posterior vibrating flexion lines.

viii) Hardy and Kapur Technique¹⁷: Using the ball portion of the T burnisher, examine the depth of the posterior palatal seal. Augment the posterior palatal seal of the denture for 4 mm from distal borders. Then the hamular notch area is narrowed to 2 mm. The posterior palatal seal is at its maximum depth in the center and minimizes to zero at its anterior and posterior border by scoring the cast.



A) Silverman's technique

B) Hardy & Kapur's Technique

Ultrasonic Technique of Recording Posterior Palatal Seal

Rajeev MN et al. used the Ultrasonic effects of nonionizing energy to displace electrons from the orbital shell. View the image of soft tissue with the help of a miniature transducer along with a real-time B-mode. Use the conventional method to mark the posterior palatal seal. Place a thin rubber on the anterior one-third of it. It also appears as an index in the monitor. Use the toothpaste as a line couplant. Locate the hard and soft palate junction using a transducer. It is done by taking it into the oral cavity and displacing it to the left of the mid-line. There is no display of Polaroid pictures as the rubber band is visualized on the posterior vibrating line and moved to the right side of the palate.¹⁹ It is indicated only for class I, II palate.

CAD-CAM Denture Base

The warpage of acrylic resin during polymerization leads to elevating of the denture base away from the posterior palatal seal.¹⁹ To minimize the dimensional change; fabricate the denture base by CAD-CAM technology. This denture gives better retention and less dimensional instability. These kinds of digital dentures have stored digital and clinical procedures, virtually thereby reducing the clinical visit. So, the patient can get spare or future dentures in one visit with more accuracy.^{20, 14}

Conclusion

Proper and effective recording of the posterior palatal seal is of great importance because it is vital to factor in establishing the peripheral seal, which enhances retention by utilizing the atmospheric pressure. Preparation of the posterior palatal seal is an integral part of maxillary complete denture fabrication. It requires an assessment of physiological and technical parameters, and careful examination during the diagnostic phase of the treatment can alleviate many potential problems. Thus, the discernment of the posterior palatal seal efficaciously is an indispensable responsibility to the dentist.

References

1. Thomason JM, Feine J, Exley C, Moynihan P, Muller F, Naert I. Mandibular two-implant-Supported overdentures as the first choices standard of care for edentulous patients-the York Consensus Statement. *Br Dent J.* 2009; 207(4):185-6.
2. Skinner E, Campbell R, Chung P. A clinical study of the forces required to dislodge maxillary denture bases of various designs. *J Am Dent Assoc.* 1953;47(6):671-80.
3. Winkler S. *Essentials of complete denture prosthodontics.* 2nd ed. New Delhi: AITBS India; 2009.
4. Glossary of Prosthodontics Terms. *J Prosthetic Dent.* 2017; 94:10-92.
5. Anthony DH, Peyton FA. Dimensional accuracy of various denture base materials. *J Prosthet Dent.* 1962; 12:67.
6. Ali Mariyam, Verma AK, Chaturvedi S, Ahmad N, Shukla A. Posterior Palatal Seal (PPS): A brief review. *Journal of Scientific and Innovative Research.* 2014; 3(6):602-5.
7. Weintraub GS. Establishing the posterior palatal seal during the final impression procedure: A functional approach. *J Am Dent Assoc.* 1977; 94:505-10.
8. Smith WG. The posterior palatal seal area in complete denture construction. *S C Dent J.* 1966; 28:66-8.
9. Nelson M. Analysis of the relationship between head posture and soft tissue contour during impression procedures, thesis. New York University College of Dentistry; New York 1970.
10. Ettinger Ronald L, Scandrett Forrest R. The posterior palatal seal. A review. *Aust Dent J.* 1980; 25(4):200.
11. Hardy IR, Kapur KK. Posterior border seal, its rationale, and importance. *J Prosthet Dent.* 1958; 8(3):386-7.
12. Calomeni AA, Feldmann EE, Kuebker's WA. A posterior palatal seal location and preparation on the maxillary complete denture cast. *J Prosthet Dent.* 1983; 5:628-30.
13. Boucher CO, Hickey JC, Zarb GA. *Prosthodontic treatment for edentulous patients* (10th ed). St Louis: The CV Mosby Co; 1975. p.141-61.
14. Bindhoo YA, Thirumurthy VR, Jacob SJ, Anjanakurien, Limson KS. Posterior palatal Seal: A literature review. *International Journal of Prosthodontics and Restorative Dentistry.* 2011;1(2):108-14.
15. Levin B. *Impressions for complete dentures.* Quintessence Publishing Co. 1984:35-70.
16. Swenson MG, Terkla LG. *Complete Dentures.* 6th ed. St. Louis: The CV Mosby Company; 1970. p.65-70,372-6.
17. William EA. A comparison of the retention of complete denture bases having different types of posterior palatal seal. *Journal of Prosthetic Dentistry.* May 1973; 29(5):484-93.
18. Silverman SI. Dimensions and displacement patterns of the posterior palatal seal. *Prosthetic Dent.* 1971; 25:470-82.
19. Rajeev MN, Appelbaum BM. An investigation of the anatomic position of the posterior seal by ultrasound. *J Prosthet Dent.* 1989; 61:331-6.

20. Goodacre BJ, Goodacre CJ, Baba NZ, Kattadiyil MT. Comparison of complete denturebase adaptation between CAD/CAM and conventional fabrication techniques. *J Prosthet Dent.* 2016; 116:249-56.