

# Hemicoronal Approach a Gateway for Treatment of ZMC Fractures

Sheeraz Badal<sup>1</sup>, Ahtesham Ahmed<sup>2</sup>, Gopal Nagargoje<sup>3</sup>, Ashutosh Dod<sup>4</sup>, Anand Mandlecha<sup>5</sup>

<sup>1</sup> Reader <sup>2</sup> Reader, <sup>3</sup> Lecturer, <sup>4</sup> PG Student, <sup>5</sup> PG Student.

Dept of Oral & Maxillofacial Surgery, MIDSR Dental College, Latur.

## Abstract:

The zygomaticomaxillary complex (ZMC) plays a crucial role in the structure, function, and aesthetic appearance of the facial skeleton. Because of its prominent position, the zygoma is the most common mid-facial bone to be fractured. Excellent exposure to multiple areas of the craniomaxillofacial region is provided through a coronal incision along with its various modifications. The main aesthetic advantage of a hidden scar in the hairline accounts for its continued popularity, and this approach is also useful for a compound fracture of ZMC. We present a case report in which we have used a hemicoronal approach for the fixation of ZMC fracture.

**Keywords:** Hemicoronal approach, Zygomaticomaxillary complex fracture (ZMC), Zygomatic

**Corresponding Author:** Dr. Ashutosh Dod, Post Graduate Student, Oral & Maxillofacial Surgery, MIDSR Dental College, Latur. Email id.: [dranandamb@gmail.com](mailto:dranandamb@gmail.com)

## INTRODUCTION:

The term zygomatico maxillary complex (ZMC) fracture refers to the bony disruption of the malar eminence at four buttresses: zygomaticomaxillary, frontozygomatic (FZ), zygomaticosphenoid, and zygomaticotemporal. The most common fracture after the nasal bone fracture is the ZMC fractures. The prominent view of the malar eminence places this structure at significant risk for fracture and the complicated 3-dimensional view of the ZMC can sometimes make the repair quite challenging.<sup>1</sup>

In the human body, face occupies the most prominent position rendering it vulnerable to injuries. The prominence of the zygomatic region predisposes it to bear the brunt of the facial injuries.<sup>2</sup> Trauma to the midface constitutes approximately 45% of zygomatic complex fractures, and their management is definitely a challenging venture for maxillofacial surgeons. Various approaches and surgical incisions are

being described to treat fractures of the ZMC, whereas the stability of these fractures is of significant concern. There have always been controversies about using the most efficient and straight forward approach to treat this fractures.<sup>3</sup>

Adequate access to the face is provided by a variety of Trans oral and hidden incisions, though maxillofacial surgeons still have some area of interest where these incisions fail to address, particularly those of upper midface and craniofacial region. A viable alternative in such complex situations is the coronal approach, which was initially described by Hartley and Kenyon in 1907 and later by Babcock in 1912. The craniomaxillofacial surgeons gained widespread admiration for the coronal approach. Tessier, then Henderson and Jackson reported excellent access when used it for Le Forte II and Le Forte III osteotomy procedures.<sup>4</sup>

The ideal surgical approach for the treatment of ZMC fractures should provide enough

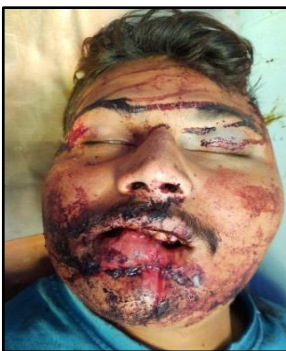exposure of the fractured segments, ensuring less potential for further injury to facial structures, and should allow for excellent cosmetic results. Different countries have different ideas for the surgical approach. Certain specialists and clinical surgeons prefer coronal scalp incision, and others insist on minimal incisions for treatment of ZMC fractures.<sup>5</sup>

There are several techniques for reducing the fractured zygomatic complex, including the Gillies temporal approach, hook elevation, and the upper buccal sulcus technique. Other includes the intranasal transantral approach, reduction through the sigmoid notch, and the modified lateral coronoid method. Elevation of the zygoma can also be accomplished through a bicoronal or lateral eyebrow incision.<sup>6</sup>

### CASE REPORT

A 35-year male patient presented to the oral and maxillofacial surgery department with a chief complaint of swelling over the left side of the face and lower chin region associated with RTA.

As per the patients, his bike had dashed with another motorcycle. When he was moved to the casualty his glass-gow coma scale was 13 (**Fig.1**).

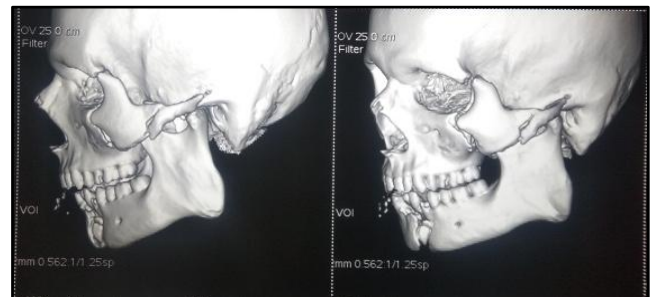


**Figure No. 1: Clinical Picture**

There was no evidence of head injury and unconsciousness. He had a positive history of bleeding through his oral cavity. All vitals were in a normal range. His previous medical history

was not significant and the personal habit revealed that he was an alcoholic since four years.

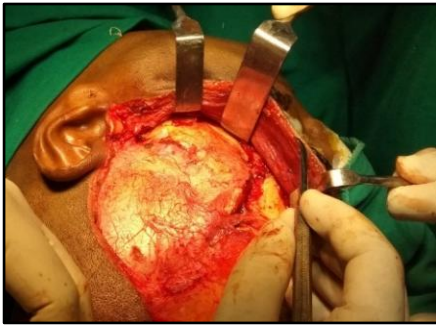
On clinical examination, Facial asymmetry was present, and occlusion was deranged. The CLW (Contused Lacerated Wound) was seen over chin involving a lip approximately 4\*5\*4 cm; CLW was also present over the supraorbital region of the left eye measuring 5\*4\*3 cm. There was a subconjunctival haemorrhage in the left eye. On palpation, the step deformity was palpated over the left frontozygomatic suture, left zygomatic arch, left infraorbital rim representing a classic picture of ZMC fracture. The step deformity was also palpated over the chin region. On a Clinical basis, a diagnosis was said to be a left Parasymphysis with a left ZMC fracture. The patient was advised for a 3D CT scan of the face that revealed the same provisional diagnosis (**Fig.2**).



**Figure No. 2: 3D CT scan of the face**

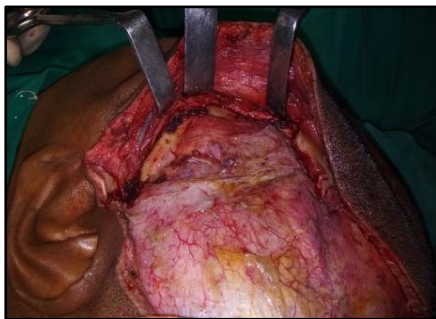All the pre-operative investigations were carried out.

Anesthetic fitness of the patient was taken and posted for surgery. The Hemicoronal approach was planned for access to the ZMC area. Scrubbing, painting, and draping were done. Marking for a hemicoronal approach was done by tattoo dye, and crosshatch was made to re-approximate the flap. The incision was kept 4 cm behind the hairline and till the tragus of the left ear. The incision was up to the depth of pericranium; further blunt dissection was done in the sub-galeal plane. Fracture sites were identified (**Fig.3**),



**Figure No. 3: Fracture Site**

And a four-point mini-fixation was done at Zygomatico-frontal suture, infra-orbital rim, Zygomatic buttress, and zygomatic arch (**Fig. 4**). After that, the mandibular vestibular incision



**Figure No. 1: Four-point mini-fixation**

was taken to reduce the left Parasymphysis fracture. It was reduced by applying two mini-plates, one on the lower border of the mandible and another one superior to it. The operated area was closed by 3-0 vicryl and sin suture as a 4-0 prolene. The patient was shifted to the recovery ward, and all the postoperative instructions were given to the patient. Sutures were removed after seven days. The patient was followed up six months; no new complaint was noted by the patient during the follow-up period.

## **DISCUSSION**

Depending on the severity of the fracture, the patient may address with various presentations of ZMC fractures. Most patients present with

swelling, edema, subcutaneous emphysema, and ecchymosis of the malar eminence. The fracture sites may often disrupt the path of the infraorbital nerve and its branches.<sup>7</sup> Currently, ZMC fractures, as well as other fractures of the maxillofacial area, are diagnosed with high-resolution and 3D CT scans. Previously, plain films were been used to diagnose fractures of the ZMC; however, with the accessibility of CT scans, CT has become the criterion standard for diagnosing ZMC fractures and guiding treatment options.<sup>9</sup> The selection of a surgical approach is vital in formulating a treatment plan for complex craniofacial problems. The surgical approach in the ZMC region depends on several factors, including the degree of access, aesthetics, and potential morbidity to critical structures of the face. Rajmohan S et al. had treated 10 cases of craniofacial problems in which five patients underwent coronal and remaining with hemicoronal approaches for the treatment of facial fractures; He observed that both approaches offer most comprehensive accessibility and visibility to the entire upper third and middle third of the face in 20 minutes.<sup>2</sup>

Kharkar V et al. described the modification of the hemicoronal approach for aesthetics as well as for better exposure area. The modification involves a back-cut incision extending anteriorly towards the mid-frontal area. In conclusion, he said that single modified hemicoronal incision gives excellent access to the fractures, being aesthetic, and less invasive.<sup>1</sup> Zhang QB et al. made 4 incisions i.e. lateral eyebrows incision, vestibular incision, temporal anterior hairline approach and subciliary incision for fixation of ZMC fractures. He found that repositioning of ZMC fractures via minimal incisions could get satisfactory results, but from his observation, these

approaches can only be used in minimally displaced ZMC fractures. As in our case, there is displaced ZMC fracture hence we used hemicoronal approach for better exposure to treat the fracture.<sup>3</sup>

Kharkar V et al, compared modified hemicoronal approach and modified lateral orbitotomy approach for the treatment of ZMC fractures, observed that The modified hemicoronal approach seems to be preferred than the modified lateral orbital approach for treating zygomatic complex fractures.<sup>5</sup> Zhuang QW et al conducted the study on open reduction and rigid fixation by a coronal approach and analyzed for indications and postoperative complications. He found that a coronal approach will facilitate accurate reduction and fixation of fragments and will allow good cosmetic results with minimal or no complications. The coronal incisions should be the first choice in case of comminuted, multiple and late zygomaticomaxillary complex fractures as in our case we choose the same.<sup>6</sup>

### CONCLUSION

The hemicoronal approach provides excellent access to the zygomatic arch and zygomatic complex helps in sound anatomical reduction and has the advantage of the scar being hidden in the hairline. The postoperative complications are minimal, minor, and outweigh the benefits for surgical treatment in any given clinical situation, as observed in this case. This proves the brilliance of the hemicoronal approach in solving surgical problems pertinent to the ZMC region with superior aesthetic outcomes.

### REFERENCES

1. Kharkar VR, Rudagi BM, Kini Y. Modification of the hemicoronal approach to treating fractures of the zygomatic complex. *Journal of*

*maxillofacial and oral surgery.* 2010; 9(3):270-2.

2. Rajmohan S, Tauro D, Bagulkar B, Vyas A. Coronal/hemicoronal approach—a gateway to a craniomaxillofacial region. *Journal of clinical and diagnostic research.* 2015; 9(8):PC01.
3. Zhang QB, Dong YJ, Li ZB, Zhao JH. Minimal incisions for treating zygomatic complex fractures. *Journal of Craniofacial Surgery.* 2011; 22(4):1460-2.
4. Sharma R, Goomer P, Sahni VR. Modified technique for fixation of zygomaticomaxillary complex fractures. *Global journal of dentistry and oral hygiene.* 2014; 2(2):59-61.
5. Kharkar VR, Rudagi BM, Halli R, Kini Y. Comparison of the modified lateral orbitotomy approach and modified hemicoronal approach in the treatment of unstable malunions of zygomatic complex fractures. *Oral Surgery, Oral Medicine, Oral Pathology, Oral Radiology, and Endodontology.* 2010; 109(4):504-9.
6. Zhuang QW, Zhang XP, Wang X, Zhang J, Li ZP, Si YM, Meng J. Coronal approach to zygomaticomaxillary complex fractures. *Eur Rev Med Pharmacol Sci.* 2015; 19(5):703-11.
7. Mesleman D, Kellman RM. Zygomaticomaxillary complex fractures. *Archives of facial plastic surgery.* 2012; 14(1):62-6.
8. Shetty SK, Saikrishna D, Kumaran S. A study on coronal incision for treating zygomatic complex fractures. *J Maxillofac Oral Surg.* 2009; 8(2):160-3.
9. Fujii N, Yamashiro M. Classification of malar complex fractures using computed tomography. *J Oral Maxillofac Surg.* 1983; 41(9):562-567.