

Interceptive Orthodontics- What? Why? When?

Vaibhav R. Ambashikar¹, Suresh Kangne², Anand Ambekar³, Pravinkumar Marure⁴, Yatish Joshi⁵, Chaitanya. Khanapure⁶.

¹Post graduate student, ²Professor & HOD, ³Professor, ^{4,5}Reader, ⁶Lecturer
Dept of Orthodontics, MIDS Dental College, Latur.

Abstract:

The major goal of modern orthodontics is to prevent or intercept developing malocclusion caused by aberrations in the developmental process. Thus, interceptive orthodontics plays an important role in reducing the development of future complex malocclusions. This article is an overview regarding the need for interceptive orthodontic techniques and the indications for the same.

Key words: Early malocclusion treatment, early orthodontic treatment, interceptive orthodontics, preventive orthodontics.

Corresponding Author: Dr. Vaibhav R. Ambashikar, Anand Sagar, Building no. 24, Flat no. 61, Bandra West, Bandra Reclamation, Mumbai-400050. Email id.: vaibhav16.xperia@gmail.com

INTRODUCTION

"An ounce of prevention is worth a pound of cure."

— Benjamin Franklin

Well-aligned teeth not only contribute to the health of the oral cavity and the stomatognathic system but also influence the personality of the person. The complex interplay between inherited and environmental influences make it difficult to evaluate the relative importance of each in the etiology of malocclusion. The long developmental period makes it possible for many external influences to affect the dentition.¹

The development of dentition and occlusion plays an important part in the craniofacial growth and helps in assimilation of facts, prediction of teeth eruption and alignment and factors influencing them and implicate clinically for treatment. The guidance of development and eruption of the deciduous, mixed, and permanent dentitions is an essential component of comprehensive oral health care for all dental patients. This guidance should play a vital role to the development of a permanent dentition that is in a steady, functional, and aesthetically acceptable occlusion and normal subsequent dentofacial development.² Normal primary dentition and normal transition from primary to the permanent dentition

are necessary to establish a normal adult occlusion. Hence one of the major goals of modern orthodontics is to understand this transition process well enough to prevent or intercept developing malocclusion caused by aberrations in the developmental process.¹ Early diagnosis and successful treatment of developing malocclusions will result in both, short-term and long-term benefits along with the goals of occlusal harmony and function and dentofacial aesthetic.²

Interceptive Orthodontics- What?

Richardson (1982) defined interceptive orthodontics as the prompt treatment of unfavourable features of a developing occlusion that may make the difference between achieving a satisfactory result by simple mechanics later, thus reducing overall treatment time and providing better stability and functional and aesthetic results.³ Thus, in simpler terms, Interceptive Orthodontics can be stated as procedures that eliminates or reduces the severity of malocclusion in the developing dentition or as described by Proffit and Ackerman that they are the measures taken in order to eliminate the developing occlusion.¹

Why Interceptive Orthodontics?

Dentists have the responsibility to recognize, diagnose, and manage or refer abnormalities in the developing dentition as dictated by the complexity of the problem and the individual clinician's training, knowledge, and experience.²

The long developmental period makes it possible for many external influences to affect the dentition.¹ Interceptive and preventive orthodontic procedures are relatively simple and inexpensive treatment approaches that target developing malocclusions during the mixed dentition. Orthodontists perceive these as useful ways to reduce the severity of malocclusions,² improve a patient's self-image, eliminate destructive habits, facilitate normal tooth eruption, and improve some growth patterns.³

Early treatment is purportedly easier to perform, less time-consuming, and less expensive. However, early treatment should not be prescribed directly. One must ask why it is needed and when it should start, and the prognosis for early treatment should be thoroughly evaluated. Of course, the most important reasons to treat early are to avoid further disturbances during eruption and occlusal development and to prevent complications like resorption of adjacent teeth and loss of bone induction or development due to non-eruption.

In a retrospective cohort study conducted by King and Brudvik in 2010 studying the effectiveness of interceptive orthodontic treatment, it was found that the index of complexity, outcomes and need (ICON) decreased by 38% in the group intervened thus suggesting that interceptive orthodontics is effective in improving a malocclusion.⁴

When to start?

In a study, the patients at risk for future orthodontic problems were identified to be 28% of those examined, and most of the developing malocclusions were judged to be suitable for interceptive orthodontic treatment.⁵ Another study of children screened in a community dental clinic at ages 9 and 11 years also found that one-third of the children would benefit from interceptive orthodontic treatment.⁶ Although interceptive orthodontic procedures often do not produce finished orthodontic results without a second phase of

treatment in the permanent dentition, it has been suggested that systematically planned interceptive treatment in the mixed dentition might contribute to a significant reduction in treatment need between the ages of 8 and 12 years, often producing results so that further need of treatment can be categorized as elective.⁴ Conceptually, the terms 'preventive' and 'interceptive' orthodontics refer to the possibility of treating young patients in ways which will obviate the need for later comprehensive treatment while operationally, they concern specific procedures or techniques in treatment of patients. Unlike preventive orthodontic procedures that are aimed at elimination of factors that may lead to malocclusion, interceptive orthodontics is undertaken at a time when the malocclusion has already developed or is developing. There are number of procedures that can be undertaken to intercept a malocclusion that is developing. Most patients who receive interceptive orthodontic treatment do not have all of their orthodontic problems addressed. However, limited interceptive treatment can reduce the need for comprehensive treatment and eliminate malocclusions considered to be medically compromising.⁷

Where to start?

"The early bird catches the worm."

-William Camden

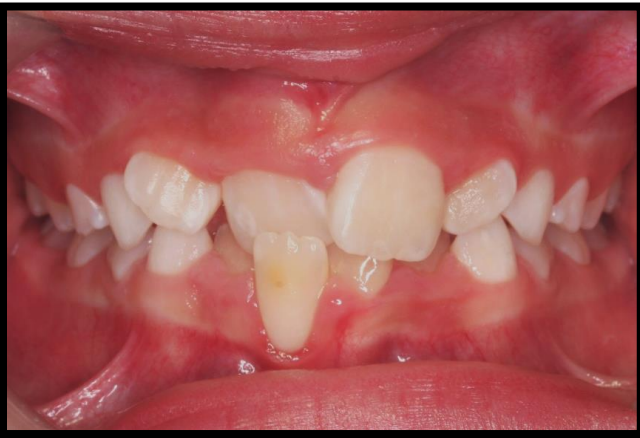Early detection and intervention of the developing malocclusion by the Dentist is of upmost priority to help the patient avoid the deleterious effects of it. The following are a few signs to intercept by the Dentist and to manage it:

Anterior crossbite

An old saying in orthodontics states "The best time to treat a cross bite is the first time it is seen".

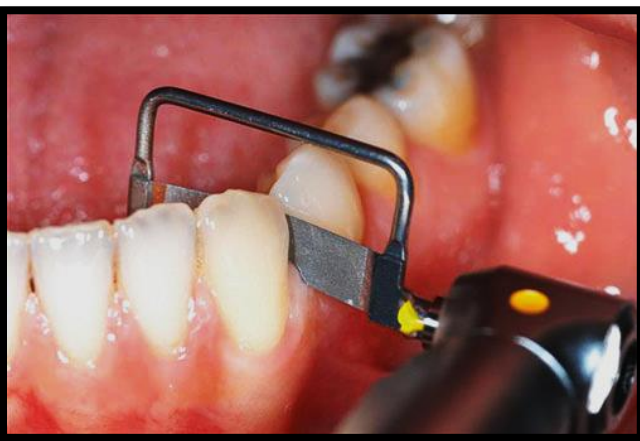
Whether the malocclusion is skeletal or dentoalveolar, the treatment of developing crossbite is recommended in primary and early mixed dentition.⁸ There are many treatment options available for correction of crossbites according to the number and site of the teeth/tooth involved, the stage of the dentition and its etiology. Few of the choices available for crossbite corrections are

Catalans appliance, tongue blade therapy, expansion appliance, cross elastics etc. Functional crossbites causing the abnormal shift of the mandible can be treated by reducing cuspal interference, particularly in the canine area. The main advantages of early treatment of anterior crossbite are to influence the process of growth in the upper jaw with simple and inexpensive appliance and also to avoid in many cases orthognathic surgery in future.⁹



Proximal Slicing

Treatment in the early mixed dentition with the eruption guidance appliance is an effective method to restore normal occlusion and eliminate the need for further orthodontic treatment with long term stability.¹⁰

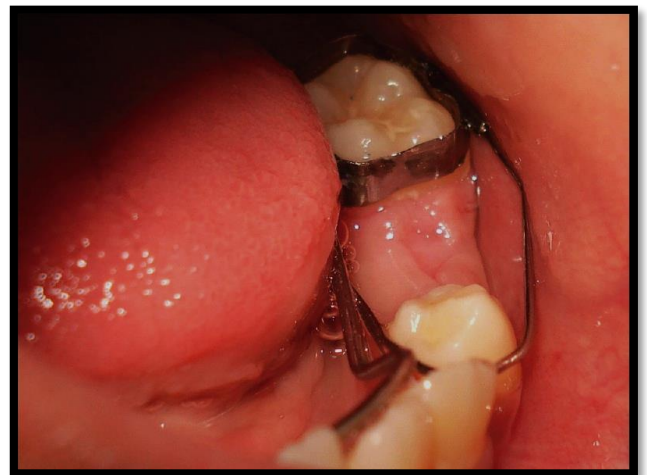


Its use has also been advocated for the improvement in the maxillo-mandibular relationship. Slicing of the

first or second deciduous molars is occasionally required to allow the permanent succedaneous teeth to erupt into its normal position. The mesial surfaces of the deciduous first molars can be sliced to prevent the crowding of lower anteriors.¹¹ When space is required for the eruption of the maxillary canine, the mesial surface of the second deciduous molar can be sliced to allow the first premolar to be pushed distally to provide space for the erupting canine.¹²

Space regainer

Premature loss of primary teeth can be a potential threat towards the disturbance of the occlusion due to the space lost by migration of the adjacent teeth. Space regainer is the ultimate choice in such situation. Open coil space regainer, Gerber's space regainer, lip bumper, free end loop space regainer, split saddle space regainer, jack screw are a few of the examples. Lip bumper has been advocated to contribute to resolution of arch perimeter deficiency in mixed dentition.^{13,14} During the transition from mixed to permanent dentition if the arch length is maintained with the use of passive lingual arch, it helps to release the leeway space for incisor alignment and also provides adequate space to resolve incisor crowding in most of the instances.¹⁵



Serial Extraction

Arch length mesial to first permanent molars tend to decrease rather than to increase on the interchange of teeth between the mixed to permanent dentition. Hence the initial objective in considering serial

extraction is to intercept a developing arch length deficiency (crowding) problem to reduce or eliminate the need for extensive appliance therapy. However, it is essential to properly weigh the advantages and disadvantages of this treatment philosophy before undertaking the extraction procedure. The ideal patient for serial extraction can be described to be an 8 year old, with normal size, shape and number of teeth, class I canine and molar relationship with minimum overjet and overbite, orthognathic or slightly bimaxillary protrusive profile, relatively severe and symmetric arch length tooth size discrepancy in the middle mixed dentition, normal eruption sequence and dental development present radiographically, normal skeletal growth pattern and normal antero-posterior, vertical and transverse relationship. Several extraction sequences have been advocated with the most common ones being that of Dewell¹⁶ and Tweed. Another treatment philosophy, called "Timely extraction" which is similar to serial extraction is the sequential removal of primary teeth, but differs in that no permanent teeth are removed, has been described by Stemm.¹⁷ It is indicated in cases with gingival recession due to labial positioning of incisors, coupled with an inadequacy of dental arch length.

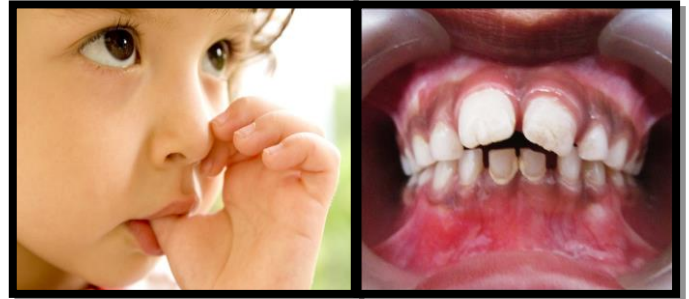INTERCEPTION OF HABITS:

Habits in the orthodontic sense refer to certain actions involving the teeth and other oral or perioral structures which are repeated often enough by some patients to have a profound and deleterious effect on the positions of teeth and occlusion. Some of the habits that can affect the oral structures are thumb sucking, tongue thrusting and mouth breathing.

Thumb sucking

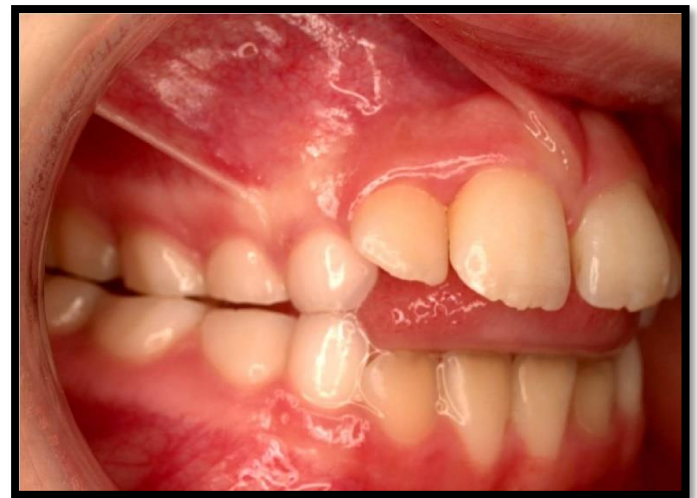Thumb sucking habit is the most frequently practiced by children and is capable of producing damaging effects on the dento-alveolar structures. The presence of this habit up to the age of 3 years is considered quite normal. Persistence of this habit beyond 3- 4 years of age can have a deleterious effect on the dento-alveolar structures and should hence be intercepted and intervened.¹⁸ In a study of thirty thumb-suckers, Lewis found that twenty-four had malocclusions, while the other six, who had broken

the habit by the age of 5 years, had normal occlusions.¹⁹ Thumb sucking is intercepted and can be resolved by use of habit breakers that could be of removable type or one that is fixed.



Tongue thrust

Tongue thrust can be stated as a condition in which the tongue makes contact with any teeth anterior to the molars during swallowing. The swallowing pattern needs to be evaluated as this deleterious habit that can clinically present with open bite and anterior proclination. The tongue thrust habit should be intercepted and managed by using habit breakers. The patient should be trained and educated on the correct technique of swallowing.²⁰



Mouth breathing

Mouth breathing habit has a profound effect on the dento-facial region. It can be obstructive or habitual in nature. It was found that mouth breathing causes considerable backward and downward rotation of

the mandible, increased overjet, increase in the mandible plane angle, a higher palatal plane, and narrowing of both upper and lower arches at the level of canines and first molars when compared to the nasal breathers. Interceptive procedures should involve identification and removal of the cause.²¹ Persistence of habitual oral breathing is an indication to use a vestibular screen to intercept the habit.



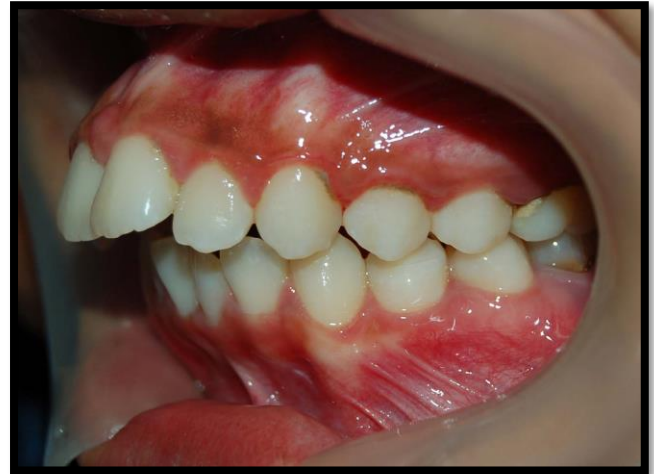Delay in tooth eruption

Eruption of deciduous teeth, their exfoliation followed by eruption of permanent dentition is an orderly sequential and age specific event. Whenever a permanent tooth fails to erupt at the appropriate time, an assessment of the local factors needs to be done to determine the cause of the delay in eruption. Mucosal barrier, over-retained primary teeth, ankylosed primary teeth and supernumerary teeth are other possible causes of non-eruption of succedaneous teeth, which should be ruled out. The management of depends on the etiology and the technique include surgical method to remove the obstruction, removal of the retained tooth, orthodontic traction, space creation and maintainance.²²

Growth Modification

Interception of skeletal malocclusion has been widely accepted in order to reduce the severity of malocclusion and normalize the skeletal relationship with the help of functional appliances. Developing skeletal class II and class III malocclusions are one of

the most challenging malocclusions to treat. Wide range of the functional appliances and the orthopaedic appliances have been used in treatment of these malocclusions. Thus, early recognition of such a problem and treating it using the remaining growth potential of the individual becomes an important aspect of interceptive orthodontics.



CONCLUSION:

General dental practitioners attend a larger number of patients compared to an orthodontist, thus an awareness regarding interception of developing malocclusion and treating it at the earliest becomes vital.

In children, though appliance therapy tends to be simpler than in adults because of growth and development and also due to transition from primary to mixed to permanent dentition, the treatment planning and monitoring are more complex. Early detection and appropriate referral of cases to an orthodontist is required whenever needed. Whenever treatment is done in children the totality of all the changes should be taken into account. Thus, interceptive orthodontics plays an important role in reducing the development of future complex malocclusions.

REFERENCES:

1. Ackerman JL, Proffit WR. Preventive and interceptive orthodontics: a strong theory proves

- weak in practice. *Angle Orthod.* 1980 Apr;50(2):75-87.
2. American Academy of Pediatric Dentistry Clinical Affairs Committee – Developing Dentition Subcommittee; American Academy of Pediatric Dentistry Council on Clinical Affairs. Guideline on management of the developing dentition and occlusion in pediatric dentistry. *Pediatr Dent.* 2005-2006;27(7 Suppl):143-55.
 3. Richardson A. “Interceptive Orthodontics” 2nd edition, London. *British Dental Journal* 1989:48-50.
 4. King GJ, Brudvik P. Effectiveness of interceptive orthodontic treatment in reducing malocclusions. *Am J Orthod Dentofacial Orthop.* 2010 Jan;137(1):18-2
 5. Karaiskos N, Wiltshire WA, Odlum O, Brothwell D, Hassard TH. Preventive and interceptive orthodontic treatment needs of an inner-city group of 6- and 9-year-old Canadian children. *J Can Dent Assoc.* 2005 Oct;71(9):649.
 6. Al Nimri K, Richardson A. Interceptive orthodontics in the real world of community dentistry. *Int J Paediatr Dent.* 2000 Jun;10(2):99-108.
 7. Jolly CJ et al. Dental effects of interceptive orthodontic treatment in a Medicaid population: Interim results from a randomized clinical trial. *Am J Orthod Dentofac Orthop.* 2010;137:324-33.
 8. Arvystas MG. The rationale for early orthodontic treatment. *Am J Orthod Dentofac Orthop.* 1998; 113:15-18.
 9. Vadiakas G, Viazis AD. Anterior crossbite correction in the early deciduous dentition. *Am J Orthod Dentofac Orthop* 1992;102:160-2.
 10. Keski-Nisula K, Hernesniemi R, Heiskanen M, Keski-Nisula L, Varrela J. Orthodontic intervention in the early mixed dentition: a prospective, controlled study on the effects of the eruption guidance appliance. *Am J Orthod Dentofac Orthop.* 2008; 133(2):254-60.
 11. Janson G et al. Treatment stability with the eruption guidance appliance. *Am J Orthod Dentofac Orthop.* 2007;131(6):717-28.
 12. Rosa M, Cozzani M, Cozzani G. Sequential slicing of lower deciduous teeth to resolve incisor crowding. *J Clin Orthod.* 1994;28(10):596-599.
 13. Nevant CT, Buschang, Alexander RG, Steffen J.M. Lip bumper therapy for gaining arch length. *Am J Orthod Dentofac Orthop.* 1991; 100:330-336.
 14. Davidovitch M, Mc Innis D. The Effects of lip bumper therapy in mixed dentition. *Am. J. Orthod. Dentofac Orthop.* 1997;111:52-58.
 15. Brennan MM, Gianelly AA. The use of lingual arch in the mixed dentition to resolve incisor crowding. *Am J Orthod Dentofac Orthop.* 2000; 117 (1): 81-8.
 16. Dewel BF. Serial Extraction in Orthodontics: Indications, objectives and treatment procedures. *Am J Orthod Dentofac Orthop.* 1954; 40:906-926.
 17. Stemm RM. Serial extraction vs. timely extraction. *Dent Surv.* 1973;49(6):35.
 18. Popovich F, Thompson GW. Thumb- and finger-sucking: its relation to malocclusion. *Am J Orthod.* 1973 Feb;63(2):148-55.
 19. Lewis. Thumbsucking: A cause of malocclusion in the deciduous teeth. *J Am Dent Assoc.* 1930;17:1060-1073.
 20. Hanson ML, Andrianopoulos MV. Tongue thrust and malocclusion: a longitudinal study. *Int J Orthod.* 1982 Jun;20(2):9-18.
 21. Harari D, Redlich M, Miri S, Hamud T, Gross M. The effect of mouth breathing versus nasal breathing on dentofacial and craniofacial development in orthodontic patients. *The Laryngoscope.* 2010;120(10):2089-2093.
 22. Pahkala R, Pahkala A, Laine T. Eruption pattern of permanent teeth in a rural community in northeastern Finland. *Acta Odontol Scand.* 1991; 49:341-9.